

CASE REPORT

Turban Pin Inhalation Syndrome with Unusually Mobile Pin from Series of Radiographs

Tin W¹, Hayati F^{1}, Muniandy R.K.², Constance L.S.L², Lim C.N.H¹, Mra A¹, Khin N.Y¹*

¹Department of Surgical Based Department, ²Department of Medicine Based Department, Faculty of Medicine and Health Sciences, University Malaysia Sabah, Kota Kinabalu, Sabah

Abstract:

Foreign Bodies (FB) dislodges are common in the ear, nose and throat especially among infants and children. Occasionally, they can accidentally be ended up in the bronchus as well. We describe a 13-year-old girl with accidental ingestion of a scarf needle pin after she was slapped on the back while biting the pin. Chest radiograph had confirmed the diagnosis of pin ingestion which is consistent with turban pin inhalation syndrome. In view of logistic and specialty issues, she was transferred to another tertiary hospital for further intervention. A series of chest radiograph showed a migratory metallic FB in different locations in the airway, which was considered as an extreme rarity. We discuss this rare entity with literature review of FB aspiration in general.

Keywords: Bronchus, Foreign body, Radiograph

Introduction:

Foreign Bodies (FB) can be dislodged in the ear, nose, throat, oesophagus and airway including trachea and bronchi. They can be in the form of bones, coins, dentures, teeth, seeds and even metallic pin. FB ingestion may occur especially while eating, talking, or laughing and even during accidental event while fixing head scarf. This is called turban pin inhalation syndrome in which it happens when the turban pins used for scarf fixation are held in between the lips and accidentally aspirated by accident. It mostly affects girls, or young women wearing turbans or

head scarfs, a traditional head scarf or hijab mostly among Muslim. Even it is rare in the literatures, it can cause significant morbidity as well as mortality [1-3].

In the case of a needle, throat pain and choking sensation are common but it can be asymptomatic occasionally. Herein, we describe a 13-year-old girl with turban pin inhalation syndrome revealing a metallic pin visualized in different locations in a series of chest radiograph and we discuss its literature review.

Case Report:

A 13-year-old female was referred from another hospital after complaining of accidental ingestion of a scarf pin. The pin was 3cm long with a small plastic knob at one end. She was putting the pin in between her lips while adjusting her head scarf, in which suddenly she was slapped jokingly on the back by her sister. The needle slipped into the throat causing it to accidentally lodge in the airway. She was brought straight to the hospital. It was confirmed by chest radiograph, the location of a long radio-opaque FB which representing the pin in the right bronchus (Fig. 1). However, there was no pneumothorax or haemothorax visualized. After sometimes, she claimed to have a discomfort sensation in the throat in which another radiograph was taken. To our surprise, the FB this time had

lodged in the trachea itself (Fig. 2). Since there was no ear, nose and throat specialist in the hospital during that time, the case had to be referred to another tertiary hospital. The distance between 2 hospitals is about 198 miles with 5 hours drive or 45 mins by flight. Upon arrival at the referred hospital, a confirmatory chest radiograph was retaken as soon as the patient arrived. New imaging had to be taken since FB was a migratory type and the long journey travel might dislodge it further.

Again to our expectation, the latest radiograph showed the FB had migrated to the left bronchus (Fig. 3). The patient was well throughout the journey as there was no stridor or desaturation noticed from the patient. After necessary preparation, the FB was taken out and retrieved under general anaesthesia by using a rigid bronchoscope. The procedure was uneventful with no complications and she was discharged after two days.

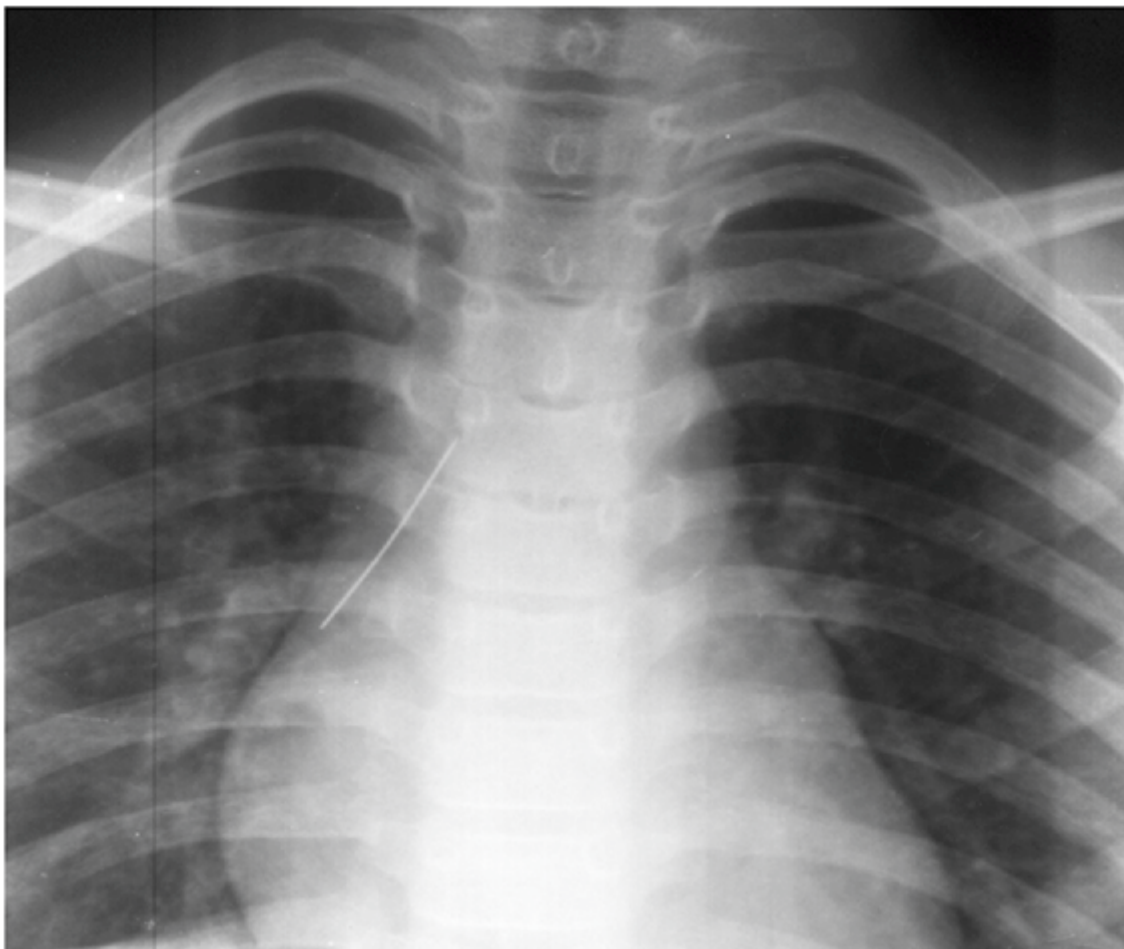


Fig. 1: Initial Chest Radiograph Taken Showing A Radio-opaque Linear FB in the Right Bronchus. No Visualized Pneumothorax, Pneumomediastinum or Haemothorax Seen

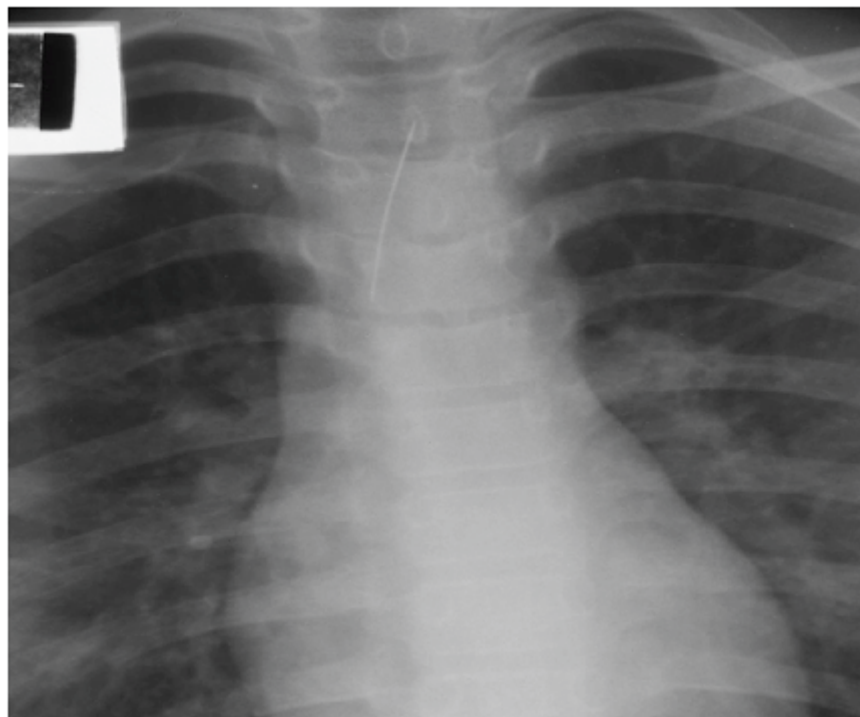


Fig. 2: Second Chest Radiograph Taken Showing the Previous Radio-opaque FB had Migrated to the Trachea

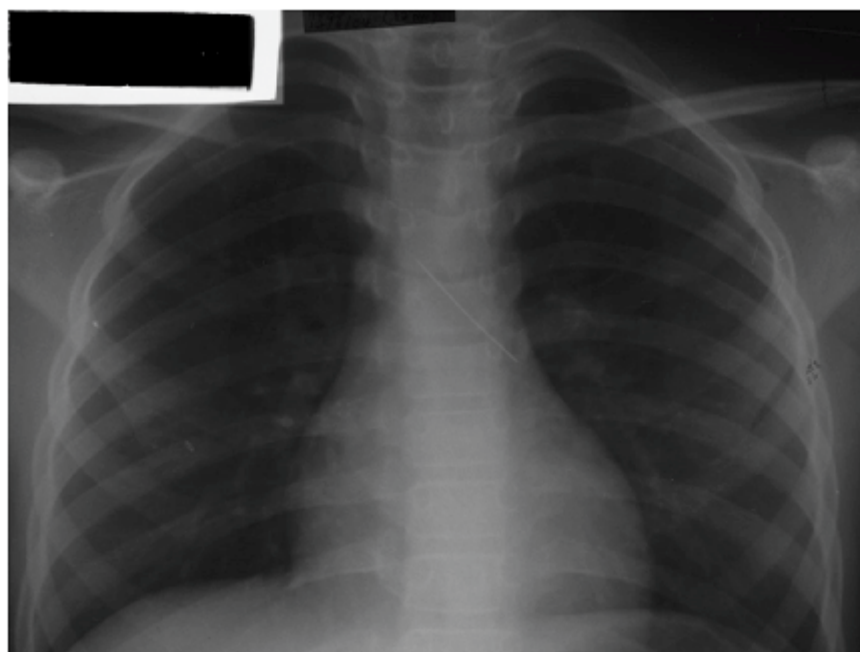


Fig. 3: Final Chest Radiograph Revealing A Sudden Migration of the FB into the Left Bronchus. No Traumatic Injury or Lung Complications could be Identified Despite of Treatment Delay or FB Migration

Discussion:

Turban pin inhalation syndrome is an extreme rarity. Out of 27 patients who were included in a Belgian study in 1999, among 113 items, there were only two pins [1-2]. In another study, out of 100 cases, the most common foreign body extracted was betel nut in 47% of the cases, only one metallic foreign body scarf pin-related hijab syndrome was noted and a new name for an unusual type of foreign body aspiration [3]. In general, aspiration of FB occurs at an estimated rate of 30/100,000 population and was responsible for 160 deaths in the United States in year 2000 [4]. It is common in children due to the tendency of them to put into the mouth when they start crawling. Thus, the peak incidence occurs between 1 to 2 years of age [4]. Older children tend to aspirate non-food materials such as pen caps, seeds and pins more frequently than younger children. Although aspiration of FB is rare in adults, some risk factors including neurologic dysfunction, dental trauma, and aspiration of larger than-normal pieces of food can expose them to aspiration. In this case, aspiration of a scarf pin can also be identified among adult.

Organic materials such as nuts, seeds, and vegetables are the most common aspirated FB. Small toys remain responsible for 5-15% for FB aspirations [5]. Pneumonia, granulations, obstructive emphysema, atelectasis, and lung abscess, are more likely to occur with these types of FB especially if delayed in diagnosis [2]. Compared to non-organic FB such as metallic pin, it would cause discomfort and bleeding if traumatic penetrating injury occurs to the bronchial mucosa. Subsequent complications such as bronchopneumonia and

lung abscess might occur in view of secondary infection.

To diagnosis a FB in the airway, there may be a definite history of inhalation of FB as in our case with prior holding of a pin in between the lips. A complaint of choking, cough, sudden onset of wheezing, acute dyspnoea, stridor as well as respiratory distress might manifest in a severe form of respiratory blockage. Anybody with choking or gagging has a sensitivity of 86-97% among patients with proven aspiration [4]. Occasionally, there can be stridor with laryngeal oedema and bronchospasm which may require intubation or tracheostomy [6]. Sometimes there can be cough and haemoptysis for months, because of granulation tissue around the foreign body and could present, as a late sign, without any foreign body history and normal chest radiograph [7].

Anatomically, the right bronchus is more vertical compared to the left side; hence any inhaled FB will be dislodged more on that side. This fact is depicted well with our case since the first chest radiograph showed similar finding. Thus, the removal or retrieval procedure is less complicated for the right sided blockage in contrast to the left side [8]. The difficulty in retrieving the FB may result in trauma to the tracheal and bronchial tree, pneumothorax, and pneumomediastinum; meanwhile prolonged removal can lead to hypoxic brain injury or even cardiac arrest [5]. The reason why there was a migratory episodes is unknown. Perhaps, it happened due to changing position of the patient during transfer and transportation in a long journey might be the best answer for the question.

The most common modalities used at present for investigation include plain chest radiographs, Computed Tomography (CT), and airway fluoroscopy. Presence of sharp, linear and elongated radio-opaque FB is pathognomonic of pin ingestion for chest radiograph. Antero-posterior and lateral views of the chest are required for better localization. Plain radiographs had a sensitivity of 73.6% and a specificity of 44.4% [4]. Unfortunately, almost 90% of foreign bodies are radio-lucent and the chest radiograph is normal in up to 30% of children who aspirate foreign bodies [9]. Late findings of traumatic pin injury may include pneumothorax, pneumomediastinum, emphysema, bronchopneumonia, and pulmonary abscess [2]. CT can be used in cases when plain radiography yields inconclusive results. Reported sensitivity approaches 100% with specificity between 66-100% [4]. CT has an advantage in potentially demonstrating a radiolucent foreign bodies but in cases of metallic pin unfortunately, it will be manifested as beam hardening artifacts [4]. Airway fluoroscopy however is used less frequently nowadays.

Usually, FB in the bronchus is removed by rigid or flexible bronchoscope by ear, nose and throat surgeon or pulmonologist. The ability to control the airway, the presence of excellent optics, a wide working channel for the passage of instruments, and the availability of a wide array of tools for foreign body removal have made rigid broncho-

scopy the instrument of choice for foreign body removal [4,8]. The disadvantages include the need for general anaesthesia and the inability to retrieve foreign bodies in the peripheral airways. A more recent series involving 1027 pediatric patients reported a 91.3% success rate in tracheobronchial foreign body removal using flexible bronchoscopy [4]. Hence, the reason of transferring our case to another tertiary hospital was to achieve these advantages.

Surgical treatment is recommended after unsuccessful bronchoscopic removal. Hence, thoracotomy is mandatory especially when the removal of a FB at sub-segmental bronchus level is needed and the FB is at permanent risk for further distal migration [2]. The rate for surgery in literature ranges from 1.6-27% [2]. The overall mortality rate from aspiration of FB is less than 1.8% but can vary by anatomic location. However, mortality rate due complete obstruction of the larynx can go up to 45% [4].

Conclusion:

This new trend of FB aspiration namely turban pin inhalation syndrome is rare but easily preventable. Counselling is mandatory for those who are actively practising head scarf wearing with pin. It is vital not to put pin in between the lips during scarf wearing. However, if we are able to diagnosis FB aspiration early, complications from the aspiration and surgery itself are avoidable.

References

1. Nagaraj N, Sehra RN, Berwal P, Choudhary S, Lal D, Kadela R, et al. A clinical study of foreign bodies in air passages. *Indian J Child Health* 2017; 4(2):151-154.
2. Hainer F, Klauß W, Wunsch L, Tüshaus L. The turban pin aspiration syndrome: Awareness for a subtype of foreign body aspiration. *JPediatrSurg Case Rep* 2016; 7:28-30.
3. Baram A, Kakamad FH, Bakir DA. Scarf pin-related hijab syndrome: A new name for an unusual type of foreign body aspiration. *J Int Med Res* 2017; 45(6):2078-2084.
4. Lowe DA, Vasquez R, Maniaci V. Foreign body aspiration in children. *Clin Pediatr Emer Med* 2015; 16(3):140-148.
5. Ambrose SE, Raol NP. Pediatric airway foreign body. *OperTech Otolaryngol Head Neck Surg* 2017; 28(4):265-269.
6. Jaiswal AA, Garg AK. Spontaneous expulsion of foreign body (sewing machine needle) from right middle lobe bronchus - a rare case report. *J Clin Diagn Res* 2014; 8(8):KD01-KD02.
7. Dar KA, Dar NH, Mehfooz N, Datta BS. Neglected tracheo-bronchial foreign bodies in adults. *Int J Res Med Sci* 2016; 4(6):2224-2228.
8. Debeljak A, Sorli J, Music E, Kecelj P. Bronchoscopic removal of foreign bodies in adults: experience with 62 patients from 1974–1998. *Eur Respir J* 2008; 14(4):792-795.
9. Haliloglu M, Ciftci AO, Oto A, Gumus B, Tanyel FC, Senocak ME, et al. CT virtual bronchoscopy in the evaluation of children with suspected foreign body aspiration. *Eur J Radiol* 2003; 48(2):188-192.

***Author for Correspondence:** Dr. Hayati F, Department of Surgical Based Department, Faculty of Medicine and Health Sciences, University Malaysia Sabah, Kota Kinabalu, Sabah
Email: firdaushayati@gmail.com Phone: +6012-9541429