

ORIGINAL ARTICLE

Oral Ulcer Healing after Treatment with Distilled Liquid Smoke of Coconut Shell on Diabetic Rats

Meircurius Dwi Condro Surboyo¹, Diah Savitri Ernawati^{1*}, Ira Arundina², RetnoPudji Rahayu³

¹Department of Oral Medicine, ²Department of Oral Biology, ³Department of Oral Pathology and Maxillofacial, Faculty of Dental Medicine, Universitas Airlangga, Jalan Prof. Dr. Moestopo No 47 Surabaya 60132, Indonesia

Abstract:

Background: Distilled liquid smoke from coconut shell (*Cocos nucifera L.*) by pyrolysis process with final temperature 400°C and then distilled in 120-150°C. The characteristics of distilled liquid smoke are yellow liquid, with acidity 2.39 and density 1.0643 g/cm³. The major identified compounds are phenol (36.6%), 2-methoxyphenol (guaiacol) (25.2%), furfural (17.8%), 2-methoxy-5-methylphenol (5.2%) and 4-ethyl-2-methoxyphenol (EMP) (3.5%) with 28 other minor constituents by GCMS. **Aim and Objectives:** Distilled liquid smoke was examined to investigate its potential therapeutic to oral ulcer healing and diabetic condition on the rat. Furthermore, the clinical oral ulcer healing was evaluated based on ulcer size and diabetic was evaluated based on Fasting Blood Glucose (FBG) and body weight changes. **Material and Methods:** Diabetes was induced by alloxan. Seventy-two hours after injection, the diabetic condition was confirmed with FBG of >200mg/dl, then the labial fornix anterior was injured to induce oral ulcer using round steel blade. **Results:** The clinical oral ulcer healing was improved after treatment with distilled liquid smoke compared to benzydamine hydrochloride and aquadest sterile for three days (p=0.005) and seven days (p=0.000). Treatment for seven days with distilled liquid smoke showed significant improvement of the body mass changes compared to benzydamine hydrochloride (p=0.008) and aquadest sterile (p=0.002). There was no improvement of FBG after treatment with distilled liquid smoke (p=0.152). **Conclusion:** Treatment with distilled liquid smoke coconut shell can improved oral

ulcer healing and body weight changes, but not FBG changes.

Keywords: Alloxan, Distilled Liquid Smoke, Coconut Shell, Oral Ulcer Healing, Diabetic

Introduction:

Liquid smoke is a product of wood smoke condensation that is burned indirectly at high temperatures [1]. Liquid smoke can be produced from coconut shell [2], oil palm shell [3], walnut [4] and rice hull [5]. Liquid smokes in Indonesia, traditionally used as a preservative in meat, chicken, fish and processed meat. Some research studies indicate that liquid smoke can make fish ball lasts up to 20 days [2]. Application of a stingray is able to keep protein content off to 33.73% and fat content of 1.84% [6]. Liquid smoke applied to meat does not cause protein damage [4]. Therefore, liquid smoke has been used as a safe natural food preservative [3].

In addition to functioning as a natural food preservative, liquid smoke from coconut shell and rice hull also has a therapeutic effect on some pathological conditions, but this potential is still not explored and analyzed. Liquid smoke from rice hull has anti-inflammatory and anti-diabetic effects [5]. The anti-inflammatory effect of liquid smoke from rice hulls can inhibit the formation of cytokines such as tumor necrosis factor (TNF-),

interleukin-1 (IL-1) and interleukin-6 (IL-6) [5]. The anti-diabetic effect of liquid smoke from rice hull has been observed. It can effect on decrease blood glucose, increase serum insulin and liver glycogen levels [7], and decrease triglycerides and cholesterol [8]. Distilled liquid smoke from coconut shells has the potential to accelerate the healing process by increasing of fibroblast [9], increasing collagen formation of traumatic with diabetes [10] and has analgesic effects [11]. These potentials may be related to the content, such as 2-methoxyphenols (guaiacol), phenol, 4-Ethyl-2-methoxyphenol (EMP) [12] and ascorbic acid [13]. Phenol and guaiacol are antioxidant compounds that can bind to free radicals. Both of these compounds bind to the Reactive Oxygen Species (ROS) and inhibit Nitric Oxide (NO), thus affecting the expression and production of proinflammatory cytokines such as TNF- α , IL-6 and IL-1 [7], and inhibit cyclooxygenase in tissue by reducing prostaglandin E2 synthesis [14].

Diabetes mellitus has micro and macrovascular complications as a result of the formation of ROS and contributes to the occurrence of inflammation, so minor trauma may potentially lead to oral ulcers, but this manifestation may be a secondary focus on the health condition [15]. Oral ulcers that occur in diabetes mellitus may experience delayed healing. Treatment for the diabetic condition, such as traumatic ulcer, may be topical antiseptics and topical anti-inflammatory. However, that therapy cannot help oral ulcer healing; only the pain disappears, but the ulcer is still persisting [16]. It is recognized that topical therapy would be the first choice of oral ulcer treatment [15]. One of the preparations used for oral ulcer therapy is benzydamine hydrochloride as mouthwashes functioning as anti-inflammatory and analgesic [17]. However, the use of these topical

preparations indicates an inadequate outcome and long-term and persistent healing processes for a longer duration [16]. Therefore, an innovation is needed to use coconut shell liquid smoke containing phenol, guaiacol and EMP as therapy in oral ulcers with diabetes mellitus, because the content possesses a role in the pathogenicity of diabetes and oral ulcer healing.

Material and Methods:

Distilled liquid smoke production:

The coconut shells were identified as a species from *Cocos nucifera L.* at Conversion Plant in Purwodadi. The coconut shell was obtained from five-six months old coconut fruits at local market in Surabaya. Distilled liquid smoke was made at the Research and Development Center of Forest Engineering and Forest Product Processing, Gunung Batu, Bogor. Five kilograms of coconut shells had been cleaned and dried was used to produce liquid smoke. Pyrolysis process conducted at 400°C with a heating rate at 3.33°C for 4.5 hours. Then, the distillation at 120°-150°C was used to produce distilled liquid smoke [10].

Animals

Ethical approval was obtained from the Health Experiment Committee, Faculty of Dental Medicine, Universitas Airlangga in Surabaya with registered number 236/HRECC.FODM/X/2016. This research was laboratory-based experimental investigation. Fifty-four male Wistar rats, two-months-old, weighing 120-160g were used as animal model for diabetic. Diabetic condition was confirmed as presenting fasting glucose >200 mg/dL seventy-two hours after injected with alloxan monohydrate (Alloxan monohydrate A7413, Sigma Aldrich., St. Louise, MO, USA) with a dose of 150 mg/kg. Oral ulcer was created 10 mm in the labial fornix incisive inferior, using a

round stainless blade, after anesthetized using a ketamine/xylazine cocktail. Oral ulcer was made after diabetic condition was confirmed. The clinical appearance of oral ulcer is a yellowish-white base with a reddish edge after 24 hours later. At this point in the process, treatment of sterile aquadest (as negative control), benzydamine hydrochloride 1.25% (Tantum Verde™, Soho, Jakarta, Indonesia) (as positive control) and distilled liquid smoke from coconut shell were performed once a day at a dose of 20µL/20g weight on the oral ulcer with the following distribution [10]:

- a) group A3: six animals were treated with the topical application of sterile aquadest for three days;
- b) group A5: six animals were treated with the topical application of sterile aquadest for five days;
- c) group A7: six animals were treated with the topical application of sterile aquadest for seven days;
- d) group B3: six animals were treated with the topical application of benzydamine hydrochloride for three days;
- e) group B5: six animals were treated with the topical application of benzydamine hydrochloride for five days;
- f) group B7: six animals were treated with the topical application of benzydamine hydrochloride for seven days;
- g) group C3: six animals were treated with the topical application of distilled liquid smoke for three days;
- h) group C5: six animals were treated with the topical application of distilled liquid smoke for five days;
- i) group C7: six animals were treated with the topical application of distilled liquid smoke for seven days.

The clinical measurement of oral ulcer was done on 24 hours after ulcer formed and the end of treatment period in each group using digital caliper (Mitutoyo Digimatic Caliper 500-196-30 6IN, Japan). The clinical oral ulcer healing (%) is the differences between the size of oral ulcer before treatment and the size of oral ulcer after treatment and then measure using formula [18]:

$$\text{Clinical oral ulcer healing (\%)} = (D_0 - D_t) / D_0 \times 100\%$$

Where D₀ is the wound diameter at day 0 and D_t is the wound diameter at a specific time point.

Fasting Blood Glucose (FBG) for each animal was measured 3 times using GlucoDR™ (AGM-2100, All Medicus, Korea): before injection with alloxan, 72 hours after injection intraperitoneally by alloxan monohydrate (Alloxan monohydrate A7413, Sigma Aldrich., St. Louise, MO, USA) and after treat for three, five and seven days. Changes in FBG are the differences between FBG after injected with alloxan and FBG after treatment [10].

The body weight for each animal measured 2 times using digital scale: after injection with alloxan and after treat for three, five and seven days. The changes of body weight consider as the differences between body weight after injection with alloxan and body weight after treatment.

Statistical analysis was performed using Statistical Package for the Social Sciences (SPSS) 20.0 software for windows 8.1 (SPSS™, Chicago, United State). Data obtained from the clinical measurement of clinical oral ulcer, FBG and body weight changes was then subjected to ANOVA analysis and, in cases of any difference between the treatment groups, subsequent post-hoc test with Least Significant Differences (LSD).

Results:

Oral ulcer after treatment for three days appeared as an ulcer with white or yellowish base and reddish edges (Fig. 1 - A3, B3 and C3). The size of the ulcer decreased after five days of treatment, which characterized by a decrease in the size of the white ulcer base, as well as reduced redness at

the edge of the ulcer (Fig. 1- A5, B5 and C5). At seven days of treatment, the ulcer had undergone a healing process, the white ulcer base has disappeared, and the ulcer edge didn't appear to be reddish and had same color as the surrounding tissue (Fig. 1- A7, B7 and C7).

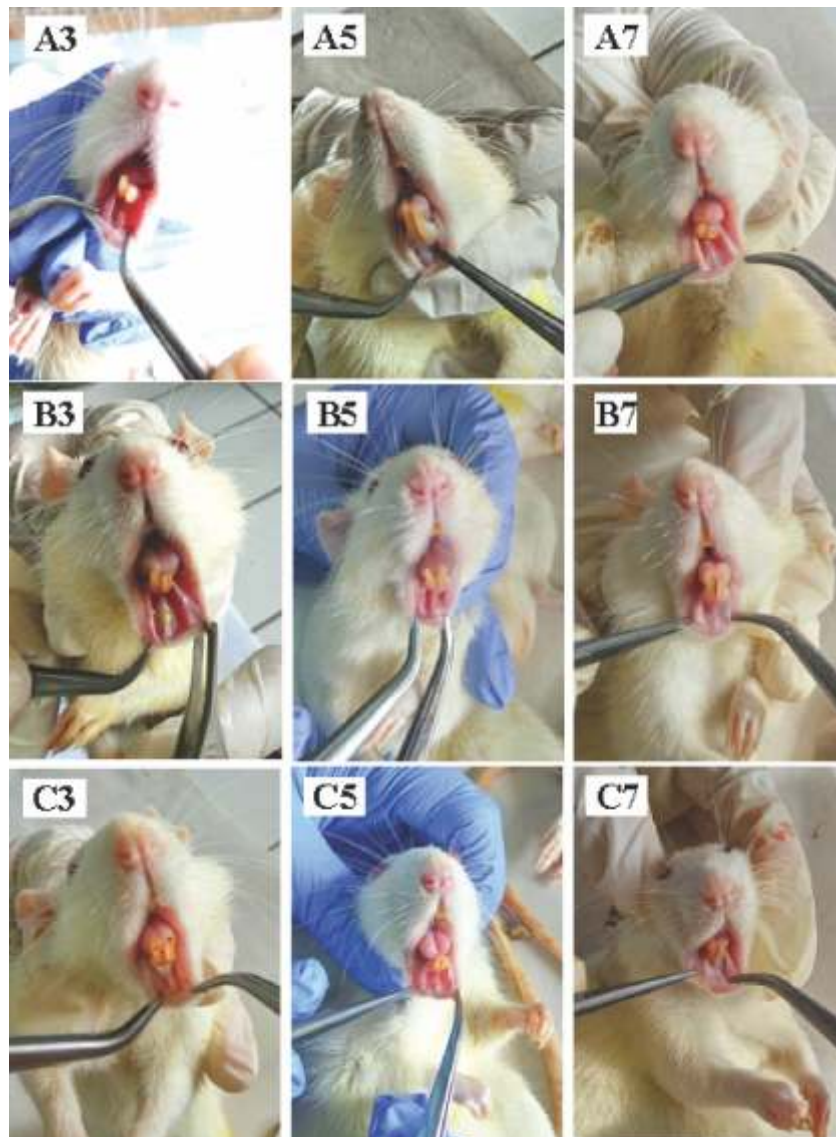


Fig. 1: Clinical Oral Ulcer Healing after Treatment on Animal. (A) Treatment with Sterile Aquadest (Control-); (B) Treatment with Benzydamine Hydrochloride (Control+); (C) Treatment with Distilled Liquid Smoke Coconut Shell; (3) Treatment for Three Days; (5) Treatment for Five Days And (7) Treatment for Seven Days.

Overall, clinically oral ulcer healing was improved after treatment with distilled liquid smoke compared with both control groups. Treatment for three days showed no significant improvement of oral ulcer size. Treatment for five days showed significantly decrease of ulcer size (58.47%) compared to benzydamine hydrochloride (31.88%) (p=0.005) and aquadest sterile (37.08%) (p=0.005) (Fig. 2). Treatment for seven days also showed significantly decrease of ulcer size (74.44%) compared to benzydamine hydrochloride (48.06%) (p=0.004) and aquadest sterile (29.86%) (p=0.000) (Fig. 2).

There were no significant differences in FBG changes after treatment with distilled liquid smoke coconut shell, benzydamine hydrochloride and aquadest sterile (p>0.00). Treatment with liquid smoke coconut shell increased FBG (82.25mg/dL) after three days, but decreased (-121.5mg/dL) for five days and decreased (-92.75mg/dL) after seven days (Fig. 3).

Treatment with liquid smoke coconut shell decreased body weight for 5g after three days, increase 5g after five days and decrease for 17.5mg after seven days. Treatment for seven days showed significant improvement with decreased body mass changes by 17.5g compared to benzydamine hydrochloride with increased body mass changes by 5g (p=0.008) and aquadest sterile with increased body mass by 10g (p=0.002) (Fig. 4).

After treatment for 3 days, there was a correlation between FBG and body weight changes (p=0.038), but there was no correlation between oral ulcer changes and body weight changes (p=0.59) and FBG changes (p=0.956). In the treatment for 7 days, there was a correlation between decrease ulcer size and body weight changes (p=0.003), but no correlation with FBG changes (p=0.267). There was no correlation between FBG and body weight changes (p=0.108).

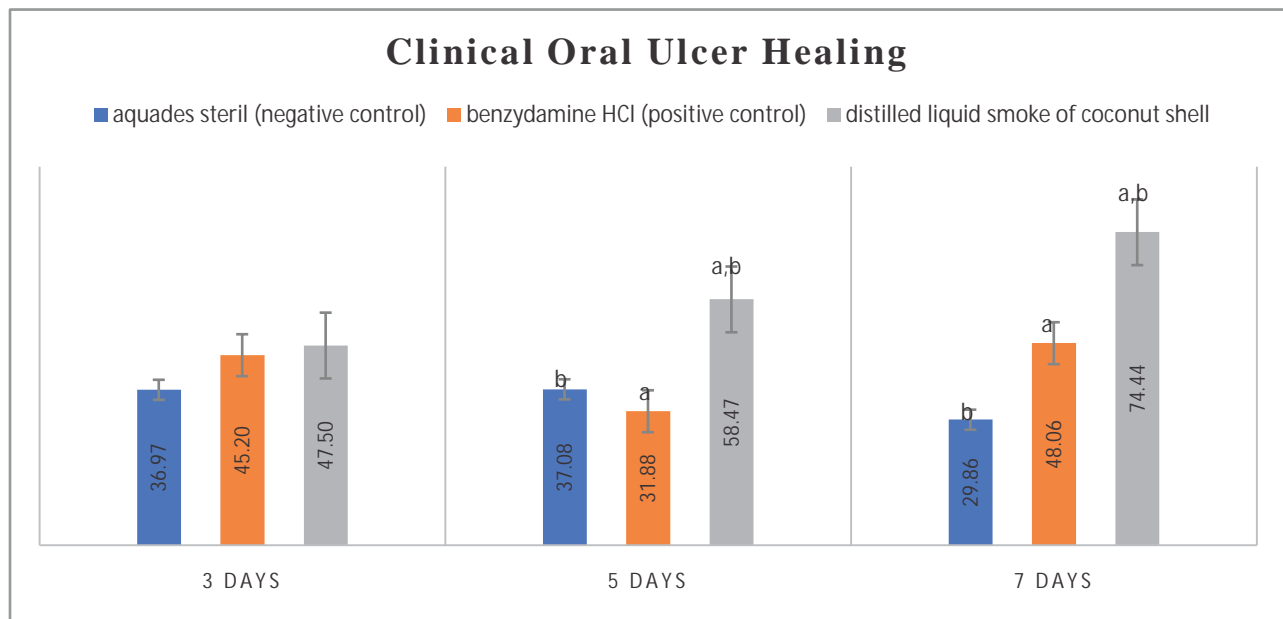


Fig. 2: Clinical Oral Ulcer Healing Based on Ulcer Size after Treatment for Three, Five and Seven Days. The Same Character Indicated Differences between Treatment Groups (P<0.001)

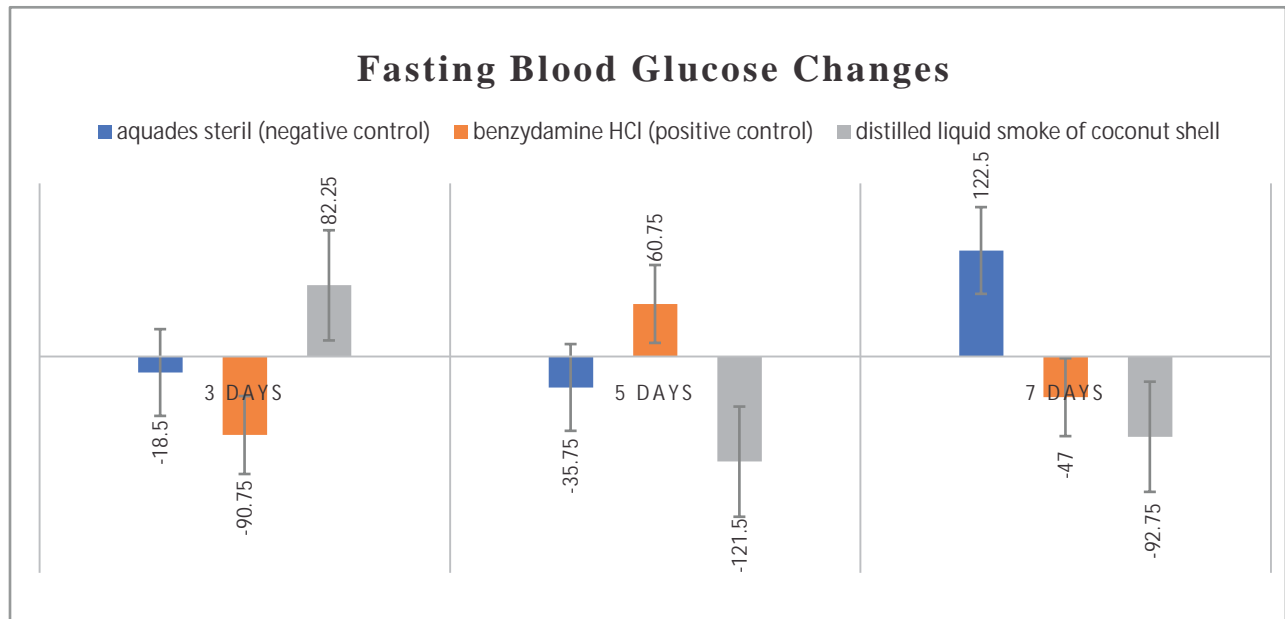


Fig. 3: FBG Changes after Treatment for Three, Five and Seven Days

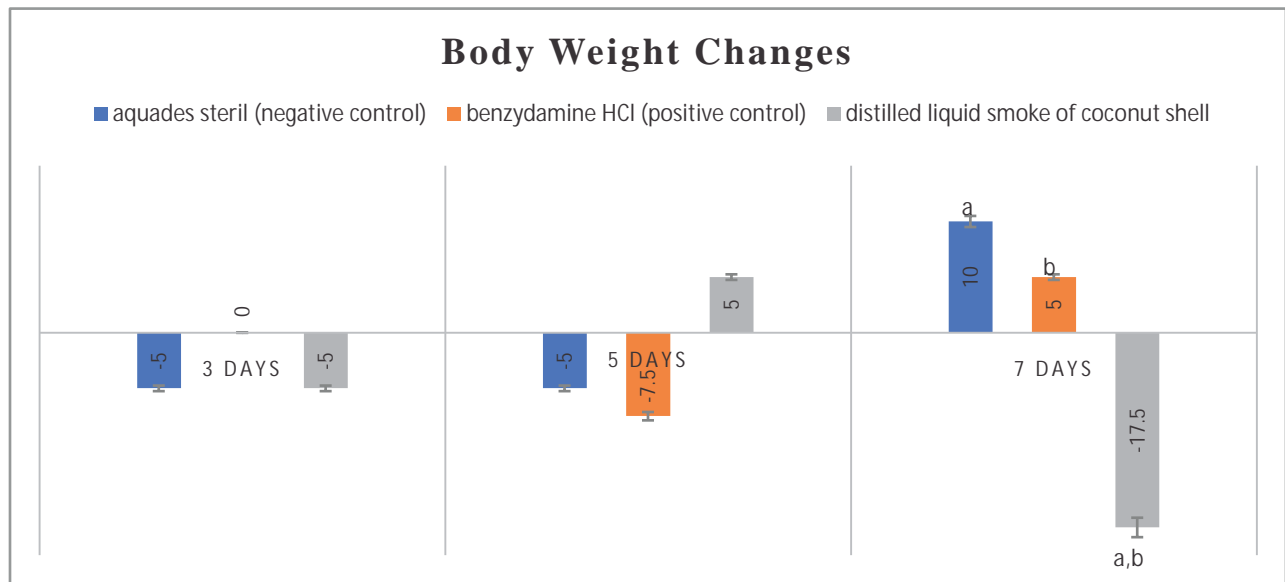


Fig. 4: Body Weight Changes after Treatment for Three, Five and Seven Days. The Same Characters Indicated Differences between Treatment Groups (p<0.05)

Discussion:

The healing process of oral ulcers in diabetes mellitus show delayed healing process [19]. The clinical appearances of delayed healing ulcer are the persistence of ulcer size and epithelial gap 3 times greater [20]. The highest inflammatory response occurs on day five after ulcer which is characterized by infiltration of PMN three times higher [21], and high lymphocyte recruitment, which further leads to the starting of a long and persistent inflammatory process [22]. Oral ulcers in diabetes mellitus stall the inflammatory phase, characterized by the continuous infiltration of neutrophils that released cytotoxic enzymes, free radicals and inflammatory mediators that cause extensive collateral damage to the surrounding tissue [23]. One of the factors that favor the occurrence of this process is the production of Advanced Glycation End (AGEs) products. AGEs can interact with cell surface proteins or extracellular matrix components resulting in the formation of cross-linked protein. AGEs can modify the plasma protein by binding with the Receptor for Advanced Glycation End (RAGE) Products on the membrane surface such as macrophages and endothelial cells. The bond leads to the formation of ROS [24, 25]. AGEs and RAGE activates Nicotinamide Adenine Dinucleotide Phosphate (NAPDH) oxidase bond which can increase intracellular ROS [26]. ROS can activate the expression of genes and proteins involved in the inflammatory cascade that is involved in the diabetic pathogenesis, such as NF κ B, AP-1, TNF- α , IL-1 and Granulocyte Macrophage Colony Stimulating Factor (GM-CSF). These cytokines have effects both systemic and tissue which play an important role in delayed healing process so acute or inflammatory phase lasts longer [24, 25].

Improved oral ulcer healing after treatment with distilled liquid smoke coconut shells marked decreased oral ulcer size. The mechanism associated with this process is closely related to the content of distilled liquid smoke coconut shell. Analysis using Gas Chromatography Mass Spectrometry (GCMS) showed 32 components identified in the liquid smoke coconut shell. The major identified compounds were phenol (36.6%), 2-methoxyphenol (guaiacol) (25.2%), furfural (17.8%), 2-methoxy-5-methylphenol (5.2%) and 4-ethyl-2-methoxyphenol (EMP) (3.5%) with 28 other minor constituents. Characteristic of distilled liquid smoke are yellow liquid, with acidity 2.39 and density 1.0643 g/cm³ [27].

These components have strong antioxidant properties and anti-inflammation a role in the healing process of oral ulcers with diabetes mellitus. Phenolic compound is highly reactive to the binding of ROS and has strong antioxidant properties [28]. The ROS binding is able to inhibit the overproduction of inflammatory mediators such as cytokines like TNF-, IL-1 and IL-6 [29]. The antioxidant properties of phenol are defined in hydroxyl group (OH) which can bind superoxide radicals (O₂⁻), thus inhibiting the production of proinflammatory cytokines [30]. Guaiacol (2-methoxyphenol) is a phenolic compound with two functional groups, hydroxyl (OH) and methoxy (-OCH₃) [28]. Guaiacol reactivity associated with the ability of the hydroxyl group to scavenge free radicals [31, 32], and has a high ionization potential, thus capable of forming strong intermolecular and intramolecular hydrogen bonds [33]. 4-Ethyl-2-Methoxyphenol (EMP) is potent scavenger of nitric oxide by binding peroxynitrite (ONOO⁻) [34]. Binding of superoxide (O²⁻) and peroxynitrite (ONOO⁻) by

guaiacol decreases the activation of transcription factors to produce pro-inflammatory cytokines [29]. This process accelerates the inflammatory phase of the healing process of oral ulcers, so the proliferative phase occurs more rapidly. Fibroblasts are the main cells in the proliferative phase of the oral ulcer healing. Treatment with liquid smoke coconut shell can increase the fibroblasts [9], and increase the number of collagens in oral ulcers with diabetes conditions [10]. On the other hand, decreased production of pro-inflammatory cytokines is causing a decrease in fibroblast apoptosis through inhibition of activation of the transcription factor FOXO1 and caspase-3 [21, 35]. Decreased fibroblast apoptosis increases the synthesis of collagen, resulting in the proliferation phase and the healing process occurs more rapidly.

Treatment with distilled liquid smoke coconut shell not only improved oral ulcer healing, but also influences the body weight. Treatment was done in this research by topical administration, and researchers believe that the dose and the administration also swallowed by the animal, so that the agents can affect their diabetes condition. Although FBG changes showed no significant result, but the body weight changes showed significant gain. The possible mechanism in decreasing fasting glucose is the ability of liquid smoke to inhibit production of pro-inflammatory cytokines TNF- α , IL-1 and IL-6. IL-1 becomes an important mediator in dysfunction and death of pancreatic β cells. These cells are susceptible to IL-1 because they express IL-1R1 higher than another cell in the body. The involvement of IL-1R1 is resulted in the activation of NF- κ B, MAPK and JNK signaling pathway, resulting in stimulation of pancreatic β -cell apoptosis and inhibiting insulin signal [36]. Inhibition of IL-1

inhibits pancreatic β cell damage by suppressing the inflammatory condition, so that insulin production is not inhibited and blood glucose is decreased [7]. The other effect of inhibition IL-1 is resulting in decreased of lipids which effect on body weight [37].

Body weight changes may also be associated with decreased blood glucose, triglycerides and cholesterol. This is supported by Yang *et al.* (2012) show the addition of liquid smoke from rice hull 0.5% and 1% in the animal diet for 7 weeks significantly reduced blood glucose, triglycerides and cholesterol. A decrease in blood glucose was significant by 33% and 38%. Triglyceride levels were also decreased by 15% and 33%. Increased HDL (high density lipoproteins) and LDL (low density lipoproteins) also occurred in the group with liquid rice hull smoke. The results of this study indicated that the addition of liquid rice hull smoke has the potential to control blood sugar, HDL and LDL in patients with obesity-related diabetes [7].

Increased oral ulcer healing after treatment with distilled liquid smoke coconut shell is associated with anti-inflammatory effects. Research conducted by Kim *et al.* showed that liquid smoke can inhibit the formation of pro-inflammatory cytokines such as tumor necrosis factor (TNF- α), interleukin-1 (IL-1) and interleukin-6 (IL-6) [5]. Pro-inflammatory cytokines are high in diabetic conditions that result in an extension of the inflammatory phase and inhibit the proliferation phase. Indicators of oral ulcer healing in diabetes not only decrease the inflammatory phase but increase fibroblasts and collagen [38]. In diabetic conditions, fibroblasts not only apoptosis process but also damaged [39]. The proliferation phase is characterized by proliferation of fibroblasts as the main ingredient

for collagen synthesis. Fibroblasts are cells that play a role in angiogenesis, regeneration of granulation tissue and epithelization [40]. Liquid smoke has been shown to increase fibroblast [9] and collagen formation [10]. Its potential can use as a mouthwash for oral ulcer therapy with diabetic, because it possesses anti-inflammatory and anti-oxidant.

Conclusion:

Treatment with distilled liquid smoke from coconut shell not only improved oral ulcer healing

by decreasing oral ulcer size but also improved body weight by decreasing body weight. Distilled liquid smoke from coconut shell can improved oral ulcer healing and body weight changes, but not FBG changes.

Acknowledgement

Author express thankful to Faculty of Dental Medicine Universitas Airlangga and Dr. Dieni Mansyur M. Eng, Chemistry Department - Indonesian Science Institute for hersupport in this research work.

References

1. Wagiman FX, Ardiansyah A, Witjaksono. Activity of coconut-shell liquid-smoke as an insecticide on the rice brown planthopper (*Nilaparvata lugens*). *ARPJ Agric Biol Sci* 2014; 9(9):293-6.
2. Zuraida I, Sukarno, Budijanto S. Antibacterial activity of coconut shell liquid smoke (CS-LS) and its application on fish ball preservation. *Int Food Res J* 2011;18:405-10.
3. Achmadi SS, Mubarik NR, Nursyamsi R, Septiaji P. Characterization of redistilled liquid smoke of oil-palm shells and its application as fish preservatives. *J Appl Sci* 2013; 13(3):401-8.
4. Yusnaini, Soeparno, Suryanto E, Armunanto R. Physical, chemical and sensory properties of kenari (*Canarium indicum* L.) shell liquid smoke-immersed-beef on different level of dilution. *J Indones Trop Anim Agric* 2012; 37(1):27-33.
5. Kim SP, Yang JY, Kang MY, Park JC, Nam SH, Friedman M. Composition of liquid rice hull smoke and anti-inflammatory effects in mice. *J Agric Food Chem* 2011; 59(9):4570-81.
6. Swastawati F, Susanto E, Cahyono B, Trilaksono WA. Sensory evaluation and chemical characteristics of smoked stingray (*dasyatis blekeery*) processed by using two different liquid smoke. *Int J Biosci Biochem Bioinform* 2012; 2(3): 212-16.
7. Yang JY, Moon E, Nam SH, Friedman M. Antidiabetic effects of rice hull smoke extract in alloxan-induced diabetic mice. *J Agric Food Chem* 2012; 60(1):87-94.
8. Yang JY, Moon E, Nam SH, Friedman M. Antidiabetic effects of rice hull smoke extract on glucose-regulating mechanism in type 2 diabetic mice. *J Agric Food Chem* 2012; 60(30):7442-49.
9. Tarawan VM, Mantilidewi KI, Dhini IM, Radhiyanti PT, Sutedia E. Coconut shell liquid smoke promotes burn wound healing. *J Evid Based Complementary Altern Med* 2016; 22(3):435-40.
10. Surboyo MDC, Arundina I, Rahayu RP. Increase of collagen in diabetes-related traumatic ulcers after the application of liquid smoke coconut shell. *Dent J (Majalah Kedokt Gigi)* 2017; 71(32):71-5.
11. Surboyo MDC, Tantiana T, Arundina I. Analgesic effect of coconut shell (*Cocos nucifera* L) liquid smoke on mice. *Dent J (Majalah Kedokt Gigi)* 2012;45(3):156-60.
12. Budijanto S, Hasbullah R, Prabawati S, Zuraida I. Identifikasi dan Uji Keamanan Asap Cair Tempurung Kelapa untuk Produk Pangan. *J Pascapanen* 2008; 5(1):32-40.
13. Desniorita, Maryam. The effect of adding liquid smoke powder to shelf life of sauce. *Int J Adv Sci Eng Inf Technol* 2015;5(6):457-9.
14. Singh S, Sheoran SS. Evaluation of the antinociceptive activity of *Amaranthus hybridus* Linn. root extracts. *Acta Pol Pharm-Drug Res* 2011;68(2):255-59.
15. Ullah A, Khan A, Khan I. Diabetes mellitus and oxidative stress – A concise review. *Saudi Pharm J* 2016;24(5):547-553.
16. Tripathi R, Tripathi K. Management of non healing oral ulcer in diabetic patient using topical application of epidermal growth factor: a case report. *Sch Acad J Biosci* 2015; 3(8):640-43.
17. Preeti L, Mangesh K, Rajkumar K, Karthik R. Recurrent aphthous stomatitis. *J Oral Maxillofac Pathol* 2011;15(3):252-6.

18. Chin C, Ng P, Ng S. Moringa oleifera standardised aqueous leaf extract-loaded hydrocolloid film dressing: in vivo dermal safety and wound healing evaluation in STZ/HFD diabetic rat model. *Drug Deliv Transl Res* 2018; (20):1-16.
19. Okonkwo UA, DiPietro LA. Diabetes and wound angiogenesis. *Int J Mol Sci* 2017; 18(7):1419.
20. Brizeno LACAC, Assreuy AMS, Alves APNN, Sousa FBFB, De B Silva PG, De Sousa SCOM, et al. Delayed healing of oral mucosa in a diabetic rat model: Implication of TNF- α , IL-1 and FGF-2. *Life Sci* 2016;155:36-47.
21. Desta T, Li J, Chino T, Graves DT. Altered fibroblast proliferation and apoptosis in diabetic gingival wounds. *J Dent Res* 2010;89(6):609-14.
22. Qing C. The molecular biology in wound healing & non-healing wound. *Chinese J Traumatol* 2017; 20(4):189-93.
23. Rosique RG, Rosique MJ, Junior JAF. Curbing inflammation in skin wound healing: A Review. *Int J Inflam* 2015; 2015(316235):1-10.
24. Ashor AW, Siervo M, Lara J, Oggioni C, Afshar S, Mathers JC. Effect of vitamin C and vitamin E supplementation on endothelial function? a systematic review and meta-analysis of randomised controlled trials. *Br J Nutr* 2015;113(8):1182-94.
25. Volpe CMO, Villar-Delfino PH, Ferreira dos Anjos PM, Nogueira-machado JA. Cellular death, reactive oxygen species (ROS) and diabetic complications. *Cell Death Dis.* 2018; 9(2):119.
26. Jud P, Sourij H. Therapeutic options to reduce advance glycation end products in patient with diabetes mellitus: A review. *Diabetes Res Clin Pract* 2019;148:54-63.
27. Surboyo MDC. Potensi liquid smoke tempurung kelapa (*Cocos nucifera* L) terhadap proses penyembuhan traumatic ulcer dengan diabetes mellitus. Universitas Airlangga; 2017. Available from: <http://repository.unair.ac.id/id/eprint/64595>
28. Scozzafava A, Passaponti M, Supuran CT, Gulcin I. Carbonic anhydrase inhibitors? guaiacol and catechol derivatives effectively inhibit certain human carbonic anhydrase isoenzymes (hCA I, II, IX and XII). *J Enzym Inhib Med Chem* 2014; 30(4):586-91.
29. Shahidi F, Yeo JD. Bioactivities of Phenolics by Focusing on Suppression of Chronic Diseases: A Review. *Int J Mol Sci.* 2018; 19(6):1573.
30. Sikorski ZE, Sinkiewicz I. Smoking - Traditional. In: Encyclopedia of Meat Science. Elsevier; 2014: 1265-72.
31. Nimse SB, Pal D. Free radicals, natural antioxidants, and their reaction mechanisms. *RSC Adv* 2015; 5:27986-8006.
32. Gulcin I, Beydemir S. Phenolic compounds as antioxidants: carbonic anhydrase isoenzymes inhibitors. *Mini-Reviews Med Chem* 2013;13:408-30.
33. Varfolomeev MA, Abaidullina DI, Solomonov BN, Verevkin SP, Emel'Yanenko VN. Pairwise substitution effects, inter- and intramolecular hydrogen bonds in methoxyphenols and dimethoxybenzenes. Thermochemistry, calorimetry, and first-principles calculations. *J Phys Chem B* 2010; 114(49):16503-16.
34. Huang M, Chang L, Sung W, Vong W, Wang B. Protective effects of three smoke flavouring phenols on oxidative damage and nitric oxide production. *Food Chem* 2011;126:1655-61.
35. Guo Y, Lin C, Xu P, Wu S, Fu X, Xia W, et al. AGEs Induced Autophagy Impairs Cutaneous Wound Healing via Stimulating Macrophage Polarization to M1 in Diabetes. *Sci Rep* 2016; 6(36416):1-16.
36. Maedler K, Dharmadhikari G, Schumann DM, Störting J. Interleukin-Targeted Therapy for Metabolic Syndrome and Type 2 Diabetes. In: Handbook of Experimental Pharmacology. Berlin: Springer, Berlin, Heidelberg; 2011: 257-78.
37. Odegaard JI, Chawla A. Through Innate Immunity. *Cold Spring Harb Perspect Med* 2012;2(3):a007724.
38. Goulding V. The effects of diabetes on collagen within wound healing. *Diabet Foot J.* 2015;18(2):75-80
39. Pang L, Wang Y, Zheng M, Wang Q, Lin H, Zhang L, et al. Transcriptomic study of high-glucose effects on human skin fibroblast cells. *Mol Med Rep* 2016;13:2627-34
40. Bainbridge P. Wound healing and the role of fibroblasts. *J Wound Care.* 2013; 22(8):407-12.

*Author for Correspondence: Diah Savitri Ernawati, Department of Oral Medicine, Faculty of Dental Medicine, Universitas Airlangga, Jalan Prof. Dr. Moestopo No 47 Surabaya 60132, Indonesia
Email: diah-s-e@fkg.unair.ac.id