

---

**CASE SERIES****Combined Non Transecting Anastomotic Urethroplasty with Buccal Mucosal Augmentation for the Management of Segmental Urethral Strictures – A Retrospective Study**

*Puvvada Sandeep<sup>1\*</sup>, Arvind Nayak K<sup>1</sup>, Prasad Mylarappa<sup>1</sup>, Avinash B Patil<sup>1</sup>, D Ramesh<sup>1</sup>*

*<sup>1</sup>Department of Urology, MS Ramaiah Medical College, Bengaluru-560054 (Karnataka) India*

---

**Abstract:**

*Background:* Urethral strictures are one of the common problems encountered by the urologist and affect one in 10,000 males. The aetiology can be secondary to inflammation, trauma or can be idiopathic. The time honoured management of strictures by dilatation was associated with high recurrence rates. Currently various techniques of urethroplasty are used in the management of strictures. We herein describe our early experience with a combined technique of non transecting urethroplasty with buccal mucosal augmentation for the management of segmental urethral strictures.

*Objective:* To report our early experience for the treatment of segmental urethral strictures with combined non transecting anastomotic urethroplasty and buccal mucosal augmentation.

*Material and Methods:* A total of three patients underwent non transecting anastomotic urethroplasty with buccal mucosal augmentation between January 2010 and December 2013 with a minimum follow up of one year.

*Results:* At one year follow up all patients were free of obstructive symptoms and, none of the patients developed recurrence. No patient developed erectile dysfunction during the course of follow up.

*Conclusion:* Non transecting anastomotic urethroplasty with buccal mucosal augmentation is a viable option for long segment strictures with diverticulum and segmental urethral strictures. This method helps in reducing the length of buccal graft required. Due to the non-transecting nature of the

surgery, blood supply to urethra is maintained, there is good graft uptake and the incidence of erectile dysfunction is reduced

**Keywords:** Non Transecting Urethroplasty, Segmental Strictures, Buccal Mucosal Graft Urethroplasty

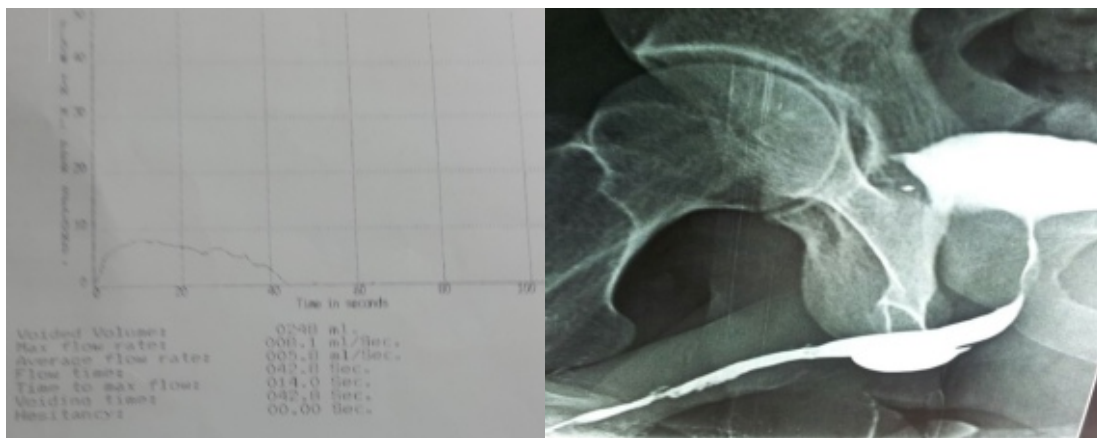
**Introduction:**

The management of urethral stricture is a challenging problem for reconstructive urologist. The presence of long segment strictures, segmental strictures and urethral diverticulum further complicates the management. Traumatic strictures are best treated with transecting end to end anastomotic urethroplasty [1]. Buccal mucosal graft urethroplasty has become a popular approach for the management of inflammatory strictures [2]. Non transecting anastomotic urethroplasty is a novel surgery in which the stricture segment is excised without transecting the spongiosum which is mainly used for treatment of short segment bulbar strictures. We herein present a series of three cases where combined non transecting anastomotic urethroplasty with buccal mucosal augmentation was performed for the management of segmental urethral strictures. To report our early experience with combined non transecting anastomotic urethroplasty with buccal mucosal augmentation for the management of segmental urethral strictures.

### Material and Methods:

Three patients underwent non transecting anastomotic urethroplasty with buccal mucosal augmentation between January 2010 and December 2013. The average age of the patients was 27 years, ranging from 21 to 34 years. None of the patients had a prior history of trauma or exposure to multiple sex partners. One patient was catheterised for 15 days previously during the course of hospital stay for femur fracture. None of the patients underwent any intervention for stricture urethra previously. All patients presented

with obstructive voiding symptoms. No evidence of lichen sclerosis was noted in any of the patients on examination and meatus was normal in all patients. Patients were evaluated with uroflometry and retrograde urography with micturating cystourethrography (Fig.1). The average Q max on uroflometry was 7.4 ml/sec ranging from 7-8.1 ml/sec. The first patient had a long segment bulbar stricture and a bulbar urethral diverticulum on retrograde urethrogram. The other two patients had segmental stricture with a long segment penile stricture and a short segment bulbar urethral stricture.



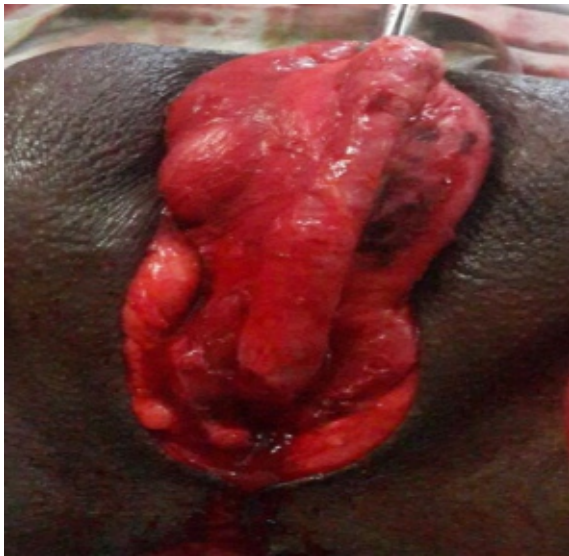**Fig. 1A: Uroflometry Suggestive of Stricture Pattern, Fig. 2B: Retrograde Urography Suggestive of Penile Stricture with Bulbar Urethral Diverticulum**

### Technique

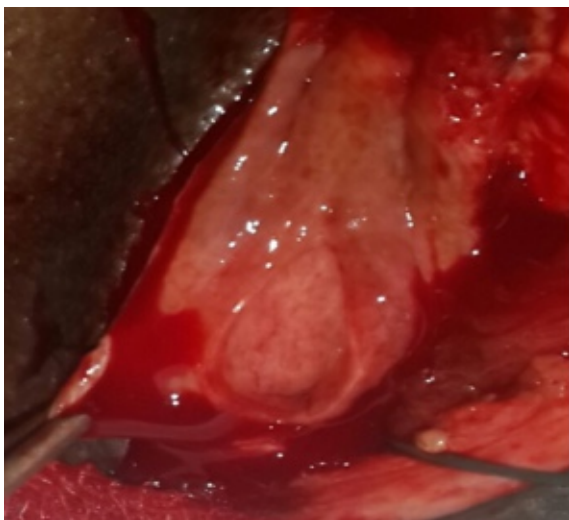
Under general anaesthesia with nasal intubation under antibiotic cover and venous thromboembolism prophylaxis, patient was placed in lithotomy position. Urethroscopy was done with a six French ureteroscope to visualise the urethra and a guide wire was passed per urethra to plan the management and facilitate surgery.

Bulbar urethra was mobilised through a midline perineal incision extending down to and through

the bulbospongiosus muscle. Left sided urethral mobilization was done in our series. Penis was inverted into the perineal incision and urethra was dissected from the corpora cavernosa (Fig.2). Urethra was then rotated exposing the dorsal surface. A dorsolateral incision was made on the urethra over the guide wire. The mucosa over the diverticulum or short segment stricture was excised without transecting the urethra (Fig.3). The mucosal ends are sutured end to end with polyglactin 3-0.



**Fig.2: Penis Being Inverted into Perineal Wound**

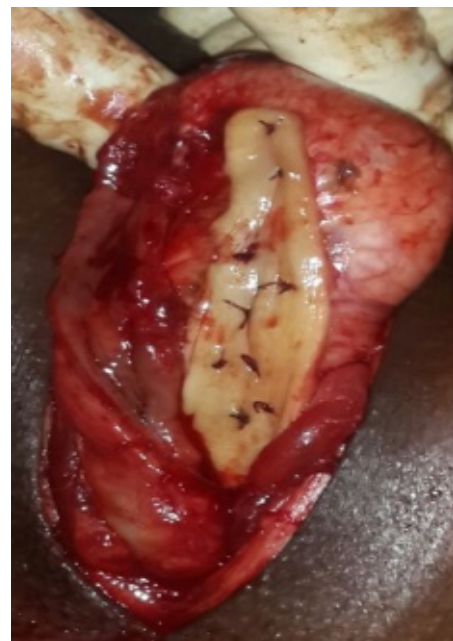

**Fig.3: Showing Urethral Diverticulum is Later Excised without Transecting Urethra**

The buccal mucosal graft was harvested after adequate exposure. The stenson's duct opening was marked opposite the second upper molar tooth. Xylocaine with 2% adrenaline was injected sub mucosally. A stay suture was placed just inside the vermilion border and two parallel incisions

were made from the anterior tonsillar pillar to the angle of the mouth. The graft was then harvested. The defect was left open to heal by secondary intention. The graft defatting was done and was refashioned to accommodate the defect.

The graft was then transferred to the perineal region and quilted to the corpora cavernosa with absorbable suture material (Fig. 4). The graft margin was sutured to the urethral margin over a 16 French silicon catheter with continuous absorbable polyglactin 4-0 suture.



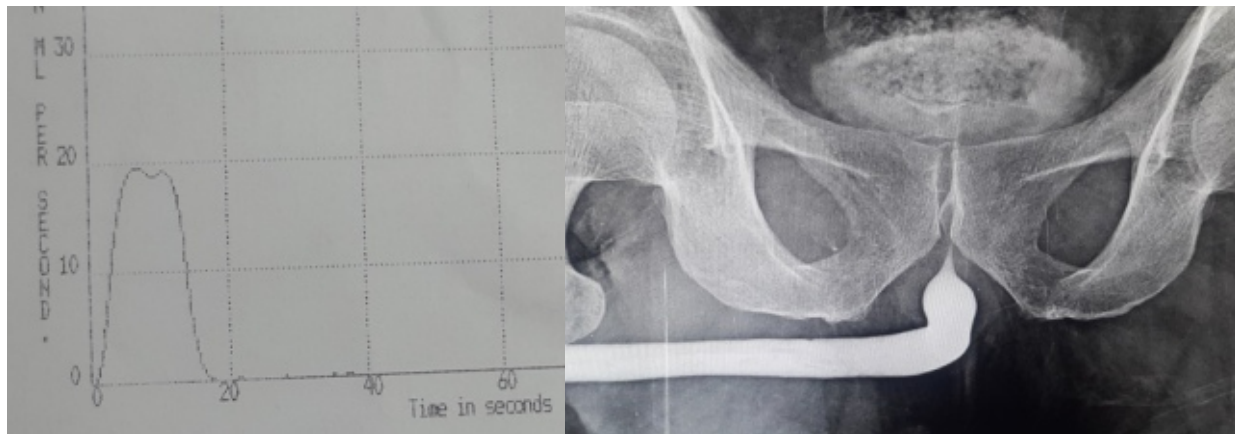
**Fig. 4: Showing Buccal Graft is quilted to the Corpora Cavernosa**

**Post-operative Care and Follow Up:**

Patients were ambulated on the first post-operative day and were given third generation cephalosporins with amikacin and metronidazole for three days. Patients were discharged on third post-operative day with oral amoxicillin and caluvlenic acid for three weeks. Patient was given

oral tolterodine 2 milligrams twice a day to prevent bladder spasms and dutasteride 0.5 milligrams once a day to prevent erections until catheter removal. Catheter was removed after

three weeks. Patients were followed up after three months with uroflometry and retrograde urethrography and later with uroflometry every three months for one year to look for recurrence.



**Fig. 5: Normal Post-Operative Uroflometry and Retrograde Urography at Three Months**

### Results:

None of the patients developed post-operative complications such as wound infection or urinary tract infection. At one year follow up all patients were free of obstructive symptoms and, none of the patients developed recurrence. No patient developed erectile dysfunction during the course of follow up.

### Discussion:

Anterior urethral strictures are one of the most common problems encountered by urologists. Bulbar urethra is probably the most common site of urethral stricture disease [1]. Panurethral strictures and segmental urethral strictures occur in 13% of cases with the common causes being lichen sclerosis, catheterization, instrumentation

and idiopathic [2]. Two of our patients had idiopathic stricture and one had stricture due to prior catheterization.

Male urethral diverticula are rare entity, majority of them being acquired and only 10-20% is congenital. The acquired causes include stricture, periurethral abscess, neurogenic bladder, instrumentation and surgery [3]. Gartabathi *et al* have proposed that diverticulum is formed secondary to obstruction and rupture of periurethral glands into the urethral lumen with subsequent epithelisation over the opening of the resulting cavity. Persistent straining leads to dilatation of the cavity and increase in size of diverticulum [4].

The management of urethral strictures depend on various factors including length, aetiology, native

urethral plate, availability of local skin and surgeon preference. Visual internal urethrotomy can be attempted in small segment strictures less than 1.5 centimetres. However, this procedure is contraindicated in penile strictures, membranous strictures and long segment bulbar strictures. Visual internal urethrotomy is associated with a recurrence rate of around 50% at two years [5]. Traumatic strictures are best treated with end to end anastomotic urethroplasty after excision of stricture segment. Inflammatory strictures are treated with staged procedures or augmented anastomosis with buccal mucosal grafts or local flaps. Staged urethroplasty is associated with a higher recurrence rate (37%) when compared to buccal mucosal graft urethroplasty (17%) in the treatment of long segment urethral strictures [6]. Patients treated with fasciocutaneous flaps have a high complication rate of about 32% [6]. Jordan *et al* have presented a novel approach of non-transecting anastomotic urethroplasty in which stricture segment is excised without transecting the urethra [7]. Mundy *et al* have further modified this approach in 2011 [8]. This procedure was proposed to minimise the trauma to urethra while maintaining the excellent results of urethroplasty. The blood supply of the urethra is from the bulbar arteries, the dorsal arteries of the penis through retrograde flow from the glans and lastly from the circumflex branches of the dorsal arteries of the penis. If the urethra is mobilised and transected, the distal urethra mainly survives due the retrograde blood flow from the glans, which may be compromised in certain patients e.g. hypospadias. In non-transecting anastomotic

urethroplasty, the vascular supply is preserved. It is best suited for patients with short segment bulbar strictures. The incidence of erectile dysfunction is significantly less (2.4%) compared to transecting urethroplasty (18-25%) [9]. In our series, this technique was used for excision of urethral diverticulum and short segment bulbar strictures.

In our series we used a combination of non-transecting anastomotic urethroplasty for the treatment of short segment bulbar strictures and urethral diverticulum along with augmented buccal mucosal urethroplasty for the management of associated long segment strictures. Blayne *et al*, in his series of 44 patients reported a success rate of 93% for augmented non transecting urethroplasty and found no difference to buccal mucosal urethroplasty in terms of recurrence [10]. The advantage of this surgery is that urethral transection can be avoided, a smaller buccal graft can be used and also the urethral plate can be reconfigured.

#### **Conclusion:**

Non transecting anastomotic urethroplasty with buccal mucosal augmentation is a viable option for long segment strictures with diverticulum and segmental urethral strictures. This method helps in reducing the length of buccal graft required. Due to the non transecting nature of the surgery, blood supply to urethra is maintained, there is good graft uptake and the incidence of erectile dysfunction is reduced. The short term results of this procedure are promising but however a longer period of follow up is required to further validate the success of this procedure.

---

**References**

1. Andrich DE, Mundy AR. What is the best technique for urethroplasty? *Eur Urol* 2008; 54(5):1031-41.
2. Lumen N, Hoebeke P, Willemsen P, De Troyer B, Pieters R, Oosterlinck W. Etiology of urethral stricture disease in the 21st century. *J Urol* 2009; 182(3):983-7.
3. Rimon U, Hertz M, Jonas P. Diverticula of the male urethra: A review of 61 cases. *Urol Radiol* 1992; 14(1):49-55.
4. Ganabathi K, Leach GE, Zimmern PE, Dmochowski R. Experience with the management of urethral diverticulum in 63 women. *J Urol* 1994; 152(5 Pt 1):1445-52.
5. Heyns CF, Steenkamp JW, De Kock ML, Whitaker P. Treatment of male urethral strictures: is repeated dilation or internal urethrotomy useful? *J Urol* 1998; 160(2):356-8.
6. Warner JN, Malkawi I, Dhradkeh M, Joshi PM, Kulkarni SB, Lazzeri M, et al. A Multi-institutional Evaluation of the Management and Outcomes of Long-segment Urethral Strictures. *Urology* 2015; 85(6):1483-7.
7. Jordan GH, Eltahawy EA, Virasoro R. The technique of vessel sparing excision and primary anastomosis for proximal bulbous urethral reconstruction. *J Urol* 2007; 177(5):1799-802.
8. Andrich DE, Mundy AR. Non-transecting anastomotic bulbar urethroplasty: a preliminary report. *BJU Int* 2012; 109(7):1090-4.
9. Bugeja S, Andrich DE, Mundy AR. Non-transecting bulbar urethroplasty. *Translational Andrology and Urology* 2015; 4(1): 41-50.
10. Welk BK, Kodama RT. The augmented nontransected anastomotic urethroplasty for the treatment of bulbar urethral strictures. *Urology* 2012; 79(4): 917-21.

**\*Author for Correspondence:** Dr.Puvvada Sandeep, Department of Urology, M S Ramaiah Medical College, Msrit post, New BEL Road, M S Ramaiah Nagar, Bengaluru, Karnataka 560054,  
Email: dr.sandeep001@gmail.com Cell: 09900400500